

Paratesticular Rhabdomyosarcoma in Young Adult- A Case Report

NAVIN KUMAR SINHA

ABSTRACT

Para testicular rhabdomyosarcoma is a rare malignant tumour, which usually presents as a painless mass in the scrotum or groin. A case of para testicular rhabdomyosarcoma in a 17-year-old male is being reported here who presented with chronic scrotal pain. Paratesticular rhabdomyosarcoma is a rare non germ cell tumour of scrotal sac in children and young adult/teens which can invade testis at presentation. Embryonal variant is the most common type. 40% cases can have metastasis to retroperitoneal lymph node. Diagnosis can be done on high degree of clinical suspicion coupled with biopsy and immunohistochemistry. Multimodality approach of treatment is often beneficial for patients.

Keywords: Embryonal, Paratesticular, Rhabdomyosarcoma

CASE REPORT

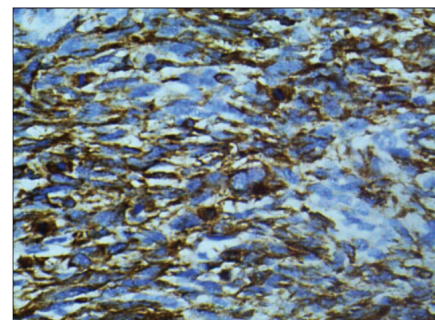
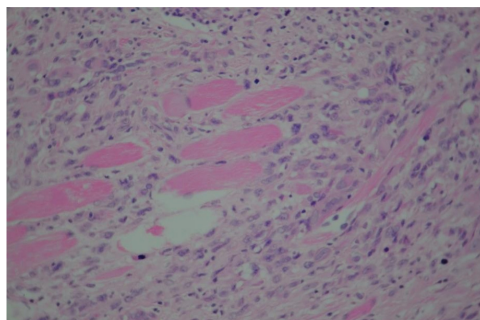
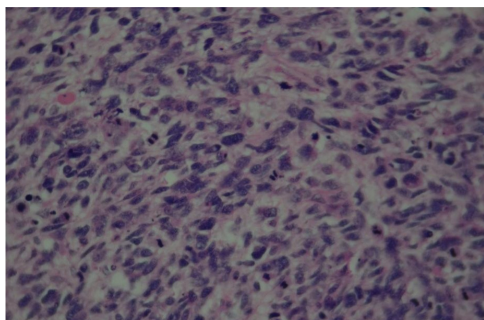
A 17-year-old male, aged normotensive, non diabetic presented with history of lump in right testis since 5-6 months. Family history or personal history was unremarkable. Biopsy showed right Para testicular rhabdomyosarcoma. USG -whole abdomen revealed normal intraabdominal organs sonologically. Moderate ascites was present. X-ray chest (PA) and abdomen (Erect position) were normal. Bone marrow aspirate and biopsy showed megaloblastoid changes only. He underwent right high inguinal orchidectomy, right hemiscrotectomy, right superficial inguinal lymph node dissection and nerve sparing retroperitoneal lymph node dissection. Cystoscopy was normal. Histopathological examination of right para testicular tumour showed rhabdomyosarcoma. A cellular tumour in para testicular area comprising of spindle to bizarre tumour cells arranged in fascicles having coarse chromatin and eosinophilic cytoplasm was observed microscopically. Scattered rhabdomyoblasts along with multinucleate giant tumour cells and cross striations in some tumour cells noted. Mitosis was brisk

(10-12/hpf including atypical form of mitosis). ([Table/Fig-1,2] H&E Stain in 40x magnification of Pleomorphic Rhabdomyosarcoma). Six right inguinal lymph nodes and 23 right retroperitoneal lymph nodes were free from tumour. Right gonadal vessels, right testis and epididymis were unremarkable. Tumour revealed immunoreactivity with Vimentin, Desmin, Myogenin and was negative for Pan Ck, S100, CD 99 and Bcl-2. ([Table/Fig-3-6] IHC in 40x magnification).

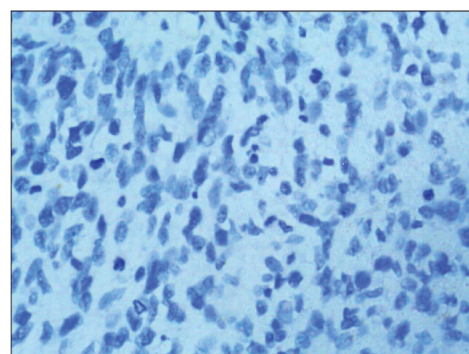
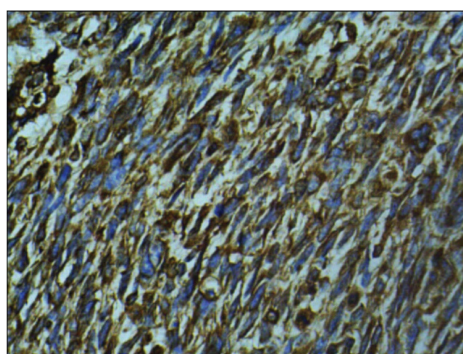
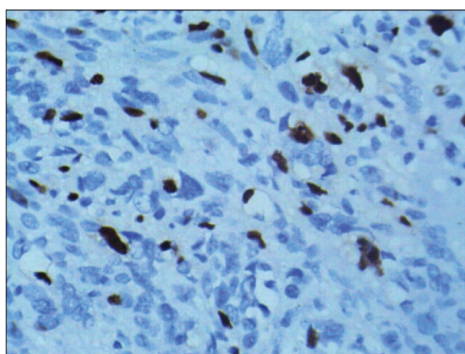
Postoperative period was uneventful. Pet- CT scan (as part of metastatic work up postsurgery) did not reveal any residual tumour or any metastatic disease. Patient has completed six cycles of adjuvant chemotherapy (VA regimen) and is on regular follow up.

DISCUSSION

Childhood Rhabdomyosarcoma is the most common soft tissue sarcoma with an annual incidence of four to seven cases per million. Paratesticular RMS accounts for 7% of all RMS and is the most common soft tissue sarcoma in childhood in this subsite. It presents with painless scrotal mass and arises from spermatic cord,



[Table/Fig-1]: Pleomorphic tumour cells with hyperchromatic irregular nuclei and mitotic figures **[Table/Fig-2]:** Rhabdomyoblast and tumour cells infiltrating between muscle bundle **[Table/Fig-3]:** IHC Desmin



[Table/Fig-4]: IHC Myogenin

[Table/Fig-5]: IHC Vimentin

[Table/Fig-6]: IHC Pan CK

epididymis and testicular envelopes. It becomes easier to identify for patient as well as doctors because of its superficial location [1,2,]. They are amenable for complete surgical resection. Overall five year survival rate is more than 80%. Complete physical examination of patient and history are the most important way to detect it in initial stage. MRI is the first and best imaging modality which provides three dimensional images for planning of surgical extent and radiation. CT scan of chest, abdomen and pelvis is done to rule out possibility of metastasis. Bone scan of entire skeleton is undertaken to see possibility of tumour mets. PET-CT is done in case of ambiguous findings on CT and MRI as well as to see response of treatment in follow up stage. Bone marrow aspiration is also done for evaluation of bone involvement (bone marrow involvement is reported in less than 2% cases). It has been observed that approximately 20% newly diagnosed patients will have one or two sites of metastasis. Hence, above modalities of investigations are essential. Normally tumour is diagnosed histopathologically on specimen collected after percutaneous or incisional or open excisional biopsy. Tissue for biopsy is sampled by three routes- percutaneous (with diagnostic yield of 90%), incisional (diagnostic yield of 100%) and excisional biopsy(with curative intent).

Three different types of RMS have been categorized based on Histo morphology of tumour cells under microscope- Embryonal (65-70%, seen in two third childhood RMS with botryoid and spindle variant), Alveolar type (20-25%) and undifferentiated/Pleomorphic type (5-10% with classic pleomorphic, round cell and spindle cell pattern). Rhabdomyoblasts is the characteristic cell but is not essential for diagnosis [3]. In Embryonal RMS, small cells with hyperchromatic nuclei, minimal cytoplasm as well as cells with rims of eosinophilic cytoplasm and spindle cells with cytoplasmic tails and variable cross striations in myxoid or collagenous stroma is seen. Tumour markers like alpha feto protein, beta HCG and carcinoembryonic antigen all are within normal range in RMS. RMS can be included in differential diagnosis of fibrosarcoma, leiomyosarcoma and liposarcoma—however these entities are more common in adults. Other common entities which can be put in differential diagnosis are- infantile fibromatosis, neuromuscular hamartoma of soft tissue and rhabdomyoma among benign entities and malignant mesothelioma, melanotic neuroectodermal tumour and desmoplastic small round cell tumour among malignant tumours in this location. All can be diagnosed morphologically and with help of IHC markers.

Multimodality approach with surgery, chemotherapy and radiation has improved prognosis in this tumour. Factors potentially affecting prognosis are local invasiveness, tumour size, morphological appearance of tumour, nodal involvement, surgical resection and age of the patient. Risk stratification into Low-A, Low- B, Intermediate, High and Intergroup Rhabdomyosarcoma group are basically used to assign appropriate treatment to patient [4]. Genitourinary location and less than 5 cm size of tumour are favourable parameters to determine prognosis. Retroperitoneal lymph node dissection has been used as staging procedure. Lymphangiography for evaluation of nodal status prior to surgery is under study for its usefulness. On IHC, Tumour cells are immunoreactive for Desmin, Vimentin, Actin and Myogenin and negative for Pan CK, S100 and CD99. Immunoreactivity for Myogenin virtually clinches diagnosis. However, in rare cases over-expression of insulin like growth factor-2 needs to be established for diagnosis on RT-PCR.

Reciprocal translocation between PAX and FKHR creates a hybrid oncogene which results in an "overdosage" of a "growth promoting gene" responsible for insulin-like growth factor Type II (IGF-II), that is located on chromosome 11 [5]. Over expression of IGF-II leads to unrestrained growth and proliferation of muscle in RMS.

RMS can spread locally, regionally (lymph nodes) and distantly (through blood). Most common sites of distant metastasis are lung, bone and bone marrow. Brain, liver and spleen are uncommon sites for distant metastasis. Metastatic disease with bone marrow involvement and aggressive behavior is more common in adult RMS. Prognosis depends on age of patient, site, size, morphology, residual tumour left after surgery and spread to other parts of body. Child above ten years of age will have high chances of nodal metastasis. However, chances of distant metastasis are one in five. Preferred route is through blood stream.

Paratesticular localization of RMS is rare and develops from mesenchymal tissue of the spermatic cord, epididymis and testicular envelope. Bimodal peaks of incidence have been observed- one at four years of age and another peak at 18 y of age. Tumour mainly presents as hard painless inguinoscrotal mass and very rarely invades scrotal skin. Rarely mass may evolve near external inguinal ring away from scrotal contents.

RMS is chemo sensitive and most common protocol is VAC- Actinomycin-D, Vincristine and Cyclophosphamide. Radical orchidectomy, hemiscrotectomy and high inguinal cord dissection with inguinal lymph node dissection is main surgical treatment. Radiotherapy is also helpful to treat residual microscopic foci of tumour.

CONCLUSION

Paratesticular RMS is a rare tumour with multimodality approach in diagnosis as well as treatment. Localized form has good prognosis and metastatic disease has poor prognosis. Retroperitoneal lymph node assessment for microscopic foci by Lymphangiography is under evaluation. Risk stratification has been done to achieve maximum benefits. Strict follow up for long term is the rule in all cases.

ACKNOWLEDGMENT

Author is thankful to MRD department for providing valuable inputs related to this case.

REFERENCES

- [1] Sultan I, Qaddoumi I, Yaser S, et al. Comparing adult and pediatric rhabdomyosarcoma in the surveillance, epidemiology and end results program, 1973 to 2005: an analysis of 2,600 patients. *J Clin Oncol*. 2009;27(20):3391-97. doi: 10.1200.
- [2] Ritesh Kumar, Rakesh Kapoor, et al. Paratesticular rhabdomyosarcoma in young adults: A tertiary care institute experience. *Indian J Urol*. 2013;29(2):110-13. doi: 10.4103/0970-1591.114030.
- [3] Parham DM, Ellison DA. Rhabdomyosarcomas in adults and children: an update. *Arch Pathol Lab Med*. 2006;130(10):1454-65.
- [4] Qualman S, Lynch J, Bridge J, et al. Prevalence and clinical impact of anaplasia in childhood rhabdomyosarcoma: a report from Soft Tissue Sarcoma Committee of the Children's Oncology Group. *Cancer*. 2008;113(11):3242-7. doi: 10.1002/cncr.23929.
- [5] Barr FG, Smith LM, Lynch JC, et al. Examination of gene fusion status in archival samples of alveolar rhabdomyosarcoma entered on the Intergroup Rhabdomyosarcoma Study-III trial: a report from the Children's Oncology Group. *J Mol Diagn*. 2006;8(2):202-28.

PARTICULARS OF CONTRIBUTORS:

1. Senior Consultant Cum Incharge, Action Cancer Hospital (www.actionhospital.com), India.

NAME, ADDRESS, E-MAIL ID OF THE CORRESPONDING AUTHOR:

Dr. Navin Kumar Sinha,
FC-34, A-4 Paschim Vihar, New Delhi-110063, India.
E-mail : nksinhaus@yahoo.com

FINANCIAL OR OTHER COMPETING INTERESTS: None.

Date of Submission: **May 05, 2014**

Date of Peer Review: **Jan 22, 2015**

Date of Acceptance: **Feb 12, 2015**

Date of Publishing: **Apr 01, 2015**